

Clinical Practice

This Journal feature begins with a case vignette highlighting a common clinical problem. Evidence supporting various strategies is then presented, followed by a review of formal guidelines, when they exist. The article ends with the authors' clinical recommendations.

HERPES ZOSTER

JOHN W. GNANN, JR., M.D.,
AND RICHARD J. WHITLEY, M.D.

A 77-year-old man reports a five-day history of burning and aching pain in his right side and a two-day history of erythema and clusters of clear vesicles, accompanied by headache and malaise. How should he be evaluated and treated?

THE CLINICAL PROBLEM

Epidemiology

Varicella–zoster virus causes two distinct syndromes. Primary infection presents as varicella (or chickenpox), a contagious and usually benign illness that occurs in epidemics among susceptible children. Subsequent reactivation of latent varicella–zoster virus in dorsal-root ganglia results in a localized cutaneous eruption termed “herpes zoster” (or “shingles”). Declining virus-specific cell-mediated immune responses, which occur naturally as a result of aging or are induced by immunosuppressive illness or medical treatments, increase the risk of shingles.¹

Over 90 percent of adults in the United States have serologic evidence of varicella–zoster virus infection and are at risk for herpes zoster.² The annualized incidence of herpes zoster is about 1.5 to 3.0 cases per 1000 persons.^{3,4} An incidence of 2.0 cases per 1000 persons would translate into more than 500,000 cases annually in the United States. Increasing age is a key risk factor for the development of herpes zoster; the incidence of shingles among persons older than 75 years of age exceeds 10 cases per 1000 person-years.³ The lifetime risk of herpes zoster is estimated to be 10 to 20 percent.⁴

From the Departments of Medicine (J.W.G., R.J.W.), Microbiology (J.W.G., R.J.W.), and Pediatrics (R.J.W.), University of Alabama at Birmingham, and the Veterans Affairs Medical Center (J.W.G.) — both in Birmingham, Ala. Address reprint requests to Dr. Gnann at the University of Alabama at Birmingham, Division of Infectious Diseases, 845 S. 19th St., BBRB 220, Birmingham, AL 35294-2170.

The other well-defined risk factor for herpes zoster is altered cell-mediated immunity. Patients with neoplastic diseases (especially lymphoproliferative cancers), those receiving immunosuppressive drugs (including corticosteroids), and organ-transplant recipients are at increased risk for shingles. However, a search for an underlying cancer is not warranted in otherwise healthy patients in whom herpes zoster develops.⁵

Herpes zoster occurs with higher frequency among persons who are seropositive for human immunodeficiency virus (HIV) than among those who are seronegative. A longitudinal study demonstrated an incidence of 29.4 cases of herpes zoster per 1000 person-years among HIV-seropositive persons, as compared with 2.0 cases per 1000 person-years among HIV-seronegative controls.⁶ Since herpes zoster may occur in HIV-infected persons who are otherwise asymptomatic, serologic testing may be appropriate in patients without apparent risk factors for shingles (e.g., healthy persons who are younger than 50 years of age).

Natural History

During the prodrome of herpes zoster, patients report headache, photophobia, and malaise, but rarely fever. The disease begins with localized abnormal skin sensations, ranging from itching or tingling to severe pain, which precede the skin lesions by one to five days. Pain of variable severity occurs in virtually all patients with acute herpes zoster. An erythematous maculopapular rash progresses to clusters of clear vesicles (Fig. 1), which continue to form for three to five days and evolve through stages of pustulation, ulceration, and crusting. Healing occurs over a period of two to four weeks, and often results in scarring and permanent changes in pigmentation. The cutaneous eruption is unilateral and does not cross the midline. Simultaneous involvement of multiple noncontiguous dermatomes virtually never occurs in immunocompetent patients, although lesions overlap adjacent dermatomes in 20 percent of cases. The presence of a few skin lesions outside the primary or adjacent dermatomes is neither unusual nor of prognostic importance in immunocompetent patients.

Diagnosis

The appearance of herpes zoster is sufficiently distinctive that a clinical diagnosis is usually accurate. However, the location or appearance of the cutaneous lesions may be atypical (especially in immunocompromised patients) and thus require laboratory confirma-

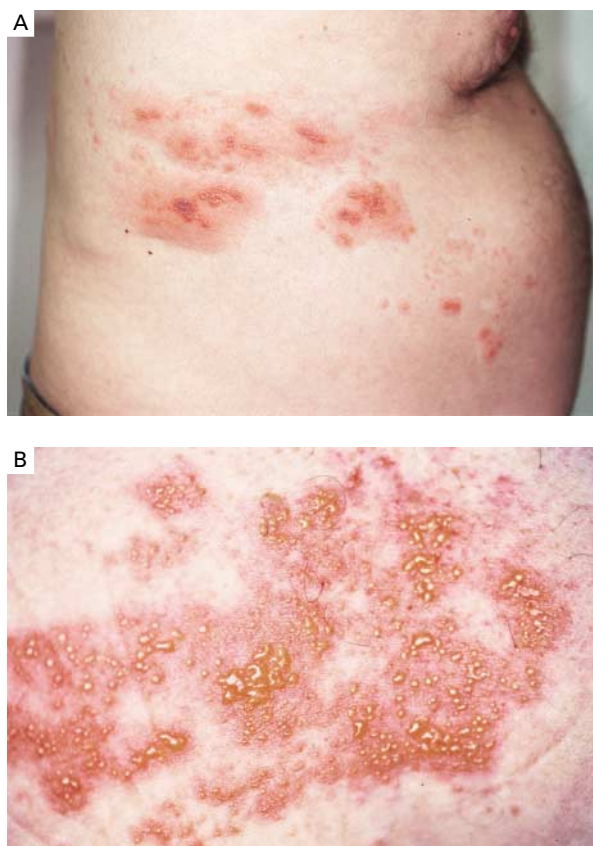


Figure 1. Acute Herpes Zoster. Panel A shows a cutaneous eruption in the right T7 dermatome. Panel B shows a close-up of fresh vesicular lesions.

tion. Viral culture is possible, but varicella–zoster virus is labile and relatively difficult to recover from swabs of cutaneous lesions. A direct immunofluorescence assay is more sensitive than viral culture and has the additional advantages of a lower cost and a more rapid turnaround time (Fig. 2).⁷ Like culture, the direct immunofluorescence assay can distinguish herpes simplex virus infections from varicella–zoster virus infections. Polymerase-chain-reaction techniques are useful for detecting varicella–zoster virus DNA in fluid and tissues.⁸

Postherpetic Neuralgia and Other Complications

Postherpetic neuralgia (defined as pain that persists more than 30 days after the onset of rash or after cutaneous healing) is the most feared complication in immunocompetent patients.⁹ Both the incidence and the duration of postherpetic neuralgia are directly correlated with the patient's age.^{4,10} The reported incidence of postherpetic neuralgia ranges from 8 to 70 percent and increases with advancing age.^{4,11–13} In

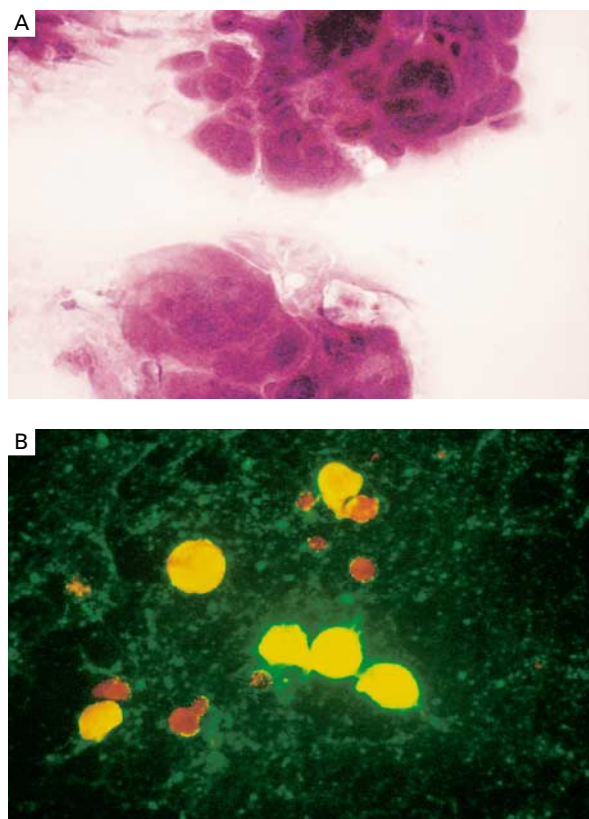


Figure 2. Diagnosis of Herpes Zoster. Cells are scraped from the base of cutaneous lesions and smeared on a glass slide for microscopy. Panel A shows a positive Tzanck smear ($\times 400$). Wright's stain demonstrates multinucleated giant cells. (Photograph courtesy of Henry Skelton, M.D.) Panel B shows a positive direct immunofluorescence assay ($\times 400$). Cells are stained with fluorescein-conjugated monoclonal antibodies against varicella–zoster virus; green fluorescence indicates the presence of varicella–zoster virus antigens.

one study, the overall prevalence of postherpetic neuralgia was 8 percent after 30 days and 4.5 percent after 60 days.¹⁰ As compared with younger patients, those who were 50 years of age or older had a prevalence of pain that was 15 and 27 times as high at 30 and 60 days, respectively. Each one-year increment in age was associated with 9 and 12 percent increases in the prevalence of postherpetic neuralgia at 30 and 60 days, respectively.¹⁰ Within the affected dermatome, patients have a variety of sensory abnormalities in addition to neuropathic pain, including allodynia, a form of hyperesthesia in which non-noxious stimuli (e.g., a light touch) are perceived as painful. Pain can persist for months and occasionally years.

Complications of herpes zoster in immunocompetent patients include encephalitis, myelitis, cranial- and peripheral-nerve palsies, and a syndrome of de-

layed contralateral hemiparesis.⁸ In the era before antiviral drugs, cutaneous dissemination of varicella-zoster virus was reported in 6 to 26 percent of immunocompromised patients.¹⁴ In most patients, disseminated disease was limited to the skin; however, 10 to 50 percent of these patients also had evidence of visceral involvement (such as pneumonitis, encephalitis, or hepatitis). Even with intravenous acyclovir therapy, the mortality rate from herpes zoster with visceral dissemination is 5 to 15 percent, with most deaths caused by pneumonitis.¹⁴

Acute retinal necrosis caused by varicella-zoster virus occasionally occurs in immunocompetent patients, although more recent reports have focused on ocular disease in HIV-infected patients.¹⁵ Visual changes begin weeks or months after the resolution of herpes zoster. The antecedent shingles may have involved any dermatome (not necessarily trigeminal), suggesting that the retinal infection is probably acquired hematogenously. The funduscopic examination shows characteristic granular, yellowish, nonhemorrhagic lesions. In HIV-infected patients, the lesions rapidly extend and coalesce, respond poorly to antiviral therapy, and almost inevitably cause blindness in the involved eye. The retinitis is less aggressive in immunocompetent patients and can often be arrested with antiviral therapy.

STRATEGIES AND EVIDENCE

Therapy for herpes zoster should accelerate healing, limit the severity and duration of acute and chronic pain, and reduce complications. In immunocompromised patients, an additional therapeutic objective is to reduce the risk of dissemination of varicella-zoster virus.

Antiviral Therapy

Three drugs — acyclovir (Zovirax), valacyclovir (Valtrex), and famciclovir (Famvir) — are approved in the United States for the treatment of herpes zoster (Table 1). In placebo-controlled trials, acyclovir (800 mg five times daily) shortened the duration of viral shedding, halted the formation of new lesions more quickly, accelerated the rate of healing, and reduced the severity of acute pain.¹⁶⁻¹⁸ Variable benefit was reported with respect to a reduction in the frequency and duration of postherpetic neuralgia. A meta-analysis of these data showed that acyclovir was significantly superior to placebo for reducing the duration of “zoster-associated pain,” defined as the continuum of pain measured from onset until final resolution.¹² Among patients who were at least 50 years of age, the median time to the resolution of pain was 41 days, as compared with 101 days in the placebo group, and the proportion with persistent pain at 6 months was 15 percent, as compared with 35 percent in the placebo group.¹²

TABLE 1. RECOMMENDED ORAL ANTIVIRAL THERAPY FOR HERPES ZOSTER IN IMMUNOCOMPETENT ADULTS WITH NORMAL RENAL FUNCTION.

Acyclovir, 800 mg every 4 hours (5 times daily) for 7 to 10 days
Famciclovir, 500 mg every 8 hours (3 times daily) for 7 days
Valacyclovir, 1000 mg every 8 hours (3 times daily) for 7 days

Valacyclovir, a prodrug of acyclovir, produces serum acyclovir levels that are three to five times as high as those achieved with oral acyclovir therapy. In a randomized trial of patients who were at least 50 years of age, valacyclovir (1000 mg every eight hours) and acyclovir resulted in equivalent rates of cutaneous healing.¹³ Valacyclovir significantly shortened the median time to the resolution of zoster-associated pain (38 days vs. 51 days, $P=0.001$). The proportion of patients experiencing pain at six months was 25.7 percent in the acyclovir group and 19.3 percent in the valacyclovir group ($P=0.02$). Extending valacyclovir therapy from 7 to 14 days did not produce any additional benefits.

Famciclovir (500 mg every eight hours), a prodrug of penciclovir, was significantly superior to placebo in reducing the duration of viral shedding, limiting the duration of new lesion formation, and accelerating healing in a placebo-controlled trial.¹⁹ In a subgroup analysis of subjects who were at least 50 years of age and who had persistent pain after skin healing, the median duration of postherpetic neuralgia was 163 days in the placebo group and 63 days in the famciclovir group ($P=0.004$).¹⁹

Valacyclovir and famciclovir were compared for the treatment of herpes zoster in immunocompetent patients and were shown to be therapeutically equivalent, in terms of both the rate of cutaneous healing and pain resolution.²⁰ At six months, 19 percent of patients in each treatment group still reported pain. Because of their superior pharmacokinetic profiles and simpler dosing regimens, valacyclovir and famciclovir are preferred to acyclovir for the treatment of herpes zoster. All three drugs are exceptionally safe and well tolerated. There are no contraindications to the use of these drugs, although an adjustment in the dose is required in patients with renal insufficiency. None of these drugs are currently approved by the Food and Drug Administration for use in pregnant women. There is no role for topical antiviral drugs in the management of herpes zoster.

Herpes Zoster Ophthalmicus

Patients with herpes zoster involving the first division of the trigeminal nerve typically present with unilateral pain and lesions on the forehead, periocular

area, and nose (Fig. 3). Without antiviral therapy, approximately 50 percent of these patients will have ocular complications (e.g., keratopathy, episcleritis, iritis, or stromal keratitis), some of which are potentially sight-threatening.²¹ Oral antiviral therapy reduces the frequency of late ocular complications from about 50 percent to 20 to 30 percent.^{13,22-25} Patients with herpes zoster ophthalmicus should be evaluated by an ophthalmologist who is experienced in the management of corneal diseases.²⁶

Herpes Zoster in HIV-Seropositive Patients

Herpes zoster in HIV-seropositive patients is usually similar to that seen in immunocompetent persons, although distinctive features, such as frequent recurrences and atypical lesions, are well described.²⁷ Orally administered acyclovir is effective for herpes zoster in HIV-infected patients.²⁸ Valacyclovir and famciclovir have not been systematically evaluated, although anecdotal experience suggests that they are efficacious. Because of the risk of relapsing infection in these patients, varicella-zoster virus disease should be treated until all lesions have completely resolved. Rare cases of disease caused by acyclovir-resistant varicella-zoster virus have been reported in patients with advanced acquired immunodeficiency syndrome, requiring therapy with alternative drugs (e.g., foscarnet).²⁹ After adjustment for age, the incidence of postherpetic neuralgia in HIV-seropositive patients does not differ substantially from that observed in immunocompetent populations.^{27,28,30}

Corticosteroids

Two large, controlled clinical trials have assessed the role of corticosteroids in combination with acyclovir. In both studies, patients receiving corticosteroids had a moderate but statistically significant acceleration in the rate of cutaneous healing and alleviation of acute pain.^{31,32} Combination therapy resulted in an improved quality of life, as measured by reductions in the use of analgesics, the time to uninterrupted sleep, and the time to resumption of usual activities.³² However, neither study demonstrated any effect of corticosteroids on the incidence or duration of postherpetic neuralgia. Corticosteroid therapy should not be used in patients at risk for corticosteroid-induced toxicity (e.g., patients with diabetes mellitus or gastritis). Combination therapy using valacyclovir or famciclovir with corticosteroids is assumed to be equally effective, but it has not been studied in clinical trials. The use of corticosteroids for herpes zoster without concomitant antiviral therapy is not recommended.

Symptomatic Treatment

Patients should keep the cutaneous lesions clean and dry to reduce the risk of bacterial superinfection. A

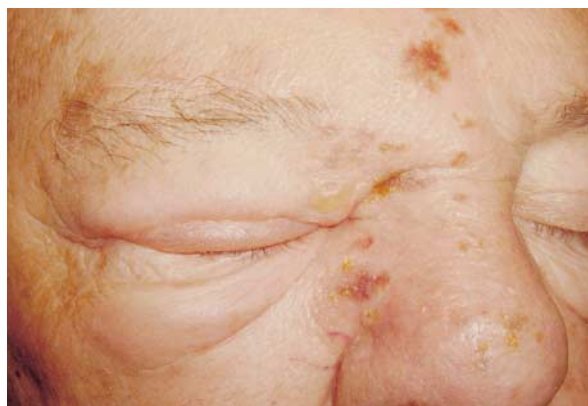


Figure 3. Acute Herpes Zoster Involving the First Division of the Trigeminal Nerve (Herpes Zoster Ophthalmicus).

Photograph courtesy of Carol Kauffman, M.D.

sterile, nonocclusive, nonadherent dressing placed over the involved dermatome will protect the lesions from contact with clothing. Neuralgic pain can be very severe and should not be underestimated by the clinician. Sympathetic-nerve blockade can provide rapid, temporary relief of severe pain.³³ Scheduled short-acting narcotic analgesics should be prescribed. For persistent pain, long-acting, controlled-release opioids (oral or transdermal) are preferred. Some models used to explain the pathogenesis of postherpetic neuralgia suggest that early attenuation of acute pain may prevent the initiation of central mechanisms of chronic pain, thereby reducing the risk of postherpetic neuralgia.³⁴

Postherpetic Neuralgia

Treatment of postherpetic neuralgia is complex, often requiring a multifaceted approach^{9,35-42} (Table 2). Clinical trials have shown that opioids, tricyclic antidepressants, and gabapentin reduce the severity or duration of postherpetic neuralgia, either as single agents or in combination.³⁶⁻⁴⁰ The adverse effects of these medications can be additive, especially in elderly patients. Topical application of lidocaine patches or capsaicin cream can provide relief for some patients.^{41,42} In a study of patients with intractable postherpetic neuralgia, intrathecal injection of methylprednisolone acetate once weekly for four weeks resulted in a significant reduction in pain.⁴³ Additional data are required to validate these promising initial results.

AREAS OF UNCERTAINTY

Does Every Patient with Herpes Zoster Require Antiviral Therapy?

Persons at highest risk for complications are elderly persons, those with herpes zoster ophthalmicus,

TABLE 2. TREATMENT OPTIONS FOR POSTHERPETIC NEURALGIA.

AGENT	INITIAL DOSE	COMMENTS	POTENTIAL ADVERSE EFFECTS
Opioids ⁴⁰	Oxycodone, 5 mg orally every 6 hours*	Total dose of 80 mg daily (or higher) potentially necessary for patients with severe pain	Sedation, nausea, dizziness, constipation, tolerance, abuse
Tricyclic antidepressants ³⁶⁻³⁸	Nortriptyline or desipramine, 10 to 25 mg orally at bedtime*	Total dose of up to 75 to 150 mg daily potentially necessary; amitriptyline also proved effective but may be poorly tolerated by elderly patients; less experience with selective serotonin-reuptake inhibitors	Sedation, confusion, anticholinergic effects (dry mouth, blurred vision, constipation, urinary retention)
Gabapentin ³⁹	300 mg orally daily	Titration of dose as necessary over a 4-week period, to a total daily dose of 3600 mg (divided into 3 doses)	Somnolence, dizziness, ataxia, nystagmus
Capsaicin (0.025–0.075% cream) ⁴¹	Topically 3 to 4 times daily	Apply only to healed, intact skin; patients may start with low-potency preparation, advance to high-potency preparation as tolerated; may take days or weeks to achieve maximal benefit; available without a prescription	Localized skin irritation and burning sensation limit use for many patients
Lidocaine (5% patch) ⁴²	Applied to painful area; up to 3 patches can be used at a time for a maximum of 12 hours	Should be applied only to healed, intact skin; patches may be cut to size; rapid onset of pain relief	Localized skin irritation; systemic toxicity from cutaneous absorption of lidocaine very rare

*Other agents are also available for use.

and immunocompromised patients. Older age, a greater degree of skin-surface area involved, and more severe pain at presentation are all predictors of persistent pain.^{10,12,30,44} Patients meeting these criteria should be targeted for therapy. All patients with acute herpes zoster ophthalmicus should receive antiviral therapy with the goal of preventing ocular complications. Some physicians still consider antiviral therapy to be optional for younger patients with uncomplicated shingles, although therapy has minimal risk and is potentially beneficial.

Can Antiviral Therapy Be Used Successfully in Patients Presenting after 72 Hours?

Trials of antiviral drugs have used similar designs: patients are enrolled within 72 hours after the onset of lesions. In practice, patients commonly present more than three days after the appearance of skin lesions, but few data are available to guide therapy in this situation. The earlier antiviral therapy is initiated, the higher the likelihood of clinical response, but some patients will benefit from these drugs even when treatment is started after three days.^{45,46} The presence of new vesicles correlates with ongoing viral replication and may be a marker for patients who might still benefit from antiviral therapy.

Can Postherpetic Neuralgia Be Prevented?

Although multiple studies have demonstrated that antiviral therapy reduces the duration of pain, antiviral drugs do not reliably prevent postherpetic neuralgia.⁴⁷⁻⁴⁹ Chronic neuropathic pain will develop in a

subgroup of patients despite appropriate antiviral treatment. Hypothetically, combining antiviral therapy with analgesics, tricyclic antidepressants, or anticonvulsants at the onset of herpes zoster could reduce the risk of postherpetic neuralgia.^{34,50,51} None of these approaches has been proved to be effective, but they are under investigation.

Can Herpes Zoster Be Prevented?

The varicella–zoster virus Oka strain vaccine is currently recommended by the Advisory Committee on Immunization Practices for universal childhood vaccination. This vaccine increases cytotoxic-lymphocyte responses specific for varicella–zoster virus in seropositive elderly persons.⁵² Whether vaccine-induced immune enhancement will reduce the incidence or severity of herpes zoster in older adults is being tested in a clinical trial.⁵³

GUIDELINES

No American professional societies have issued formal management guidelines.

CONCLUSIONS AND RECOMMENDATIONS

Herpes zoster can occur in anyone who has had varicella but is more common with increasing age and in immunocompromised patients. The diagnosis is usually made clinically, but a direct immunofluorescence assay may be useful in atypical cases. Acyclovir, valacyclovir, and famciclovir are approved for the treatment of herpes zoster. These drugs are well tolerated and are similar in terms of both efficacy and safety. How-

ever, because of their improved pharmacokinetic characteristics and simpler dosing regimens, valacyclovir and famciclovir are the preferred drugs for the treatment of herpes zoster. Older patients, especially those over 60 years of age who have severe pain at presentation, are at increased risk for more severe disease and complications and should, like the patient described in the case vignette, be targeted for antiviral therapy. Antiviral therapy is mandatory for patients presenting with herpes zoster ophthalmicus, primarily to prevent potentially sight-threatening ocular complications. To reduce the duration and severity of acute symptoms, adjunctive therapy with corticosteroids can be considered in older patients who have no contraindications. The potential for severe pain with herpes zoster should not be underestimated, and potent analgesics will often be needed. No single treatment has proved effective for postherpetic neuralgia. Combination therapy and a consultation with a pain-management specialist are often required.

Supported by contracts (NO1-AI-15113, NO1-AI-62554, and NO1-AI-12667) with the Virology Branch, Division of Microbiology and Infectious Diseases, National Institute of Allergy and Infectious Diseases; by a grant (RR-032) from the Division of Research Resources of the National Institutes of Health; and by a grant from the state of Alabama.

We are indebted to Robert Dworkin, Ph.D., for helpful discussions related to postherpetic neuralgia.

REFERENCES

- Cohen JI, Brunell PA, Straus SE, Krause PR. Recent advances in varicella-zoster virus infection. *Ann Intern Med* 1999;130:922-32.
- Choo PW, Donahue JG, Manson JE, Platt R. The epidemiology of varicella and its complications. *J Infect Dis* 1995;172:706-12.
- Donahue JG, Choo PW, Manson JE, Platt R. The incidence of herpes zoster. *Arch Intern Med* 1995;155:1605-9.
- Ragozzino MW, Melton LJ III, Kurland LT, Chu CP, Perry HO. Population-based study of herpes zoster and its sequelae. *Medicine (Baltimore)* 1982;61:310-6.
- Idem*. Risk of cancer after herpes zoster: a population-based study. *N Engl J Med* 1982;307:393-7.
- Buchbinder SP, Katz MH, Hessel NA, et al. Herpes zoster and human immunodeficiency virus infection. *J Infect Dis* 1992;166:1153-6.
- Dahl H, Marcocchia J, Linde A. Antigen detection: the method of choice in comparison with virus isolation and serology for laboratory diagnosis of herpes zoster in human immunodeficiency virus-infected patient. *J Clin Microbiol* 1997;35:345-9.
- Gilden DH, Kleinschmidt-DeMaster BK, LaGuardia JJ, Mahalingam R, Cohrs RJ. Neurologic complications of the reactivation of varicella-zoster virus. *N Engl J Med* 2000;342:635-45.
- Kost RG, Straus SE. Postherpetic neuralgia — pathogenesis, treatment, and prevention. *N Engl J Med* 1996;335:32-42.
- Choo PW, Galil K, Donahue JG, Walker AM, Spiegelman D, Platt R. Risk factors for postherpetic neuralgia. *Arch Intern Med* 1997;157:1217-24.
- de Moragas JM, Kierland RR. The outcome of patients with herpes zoster. *Arch Dermatol* 1957;75:193-6.
- Wood MJ, Kay R, Dworkin RH, Soong S-J, Whitley RJ. Oral acyclovir therapy accelerates pain resolution in patients with herpes zoster: a meta-analysis of placebo-controlled trials. *Clin Infect Dis* 1996;22:341-7.
- Beutner KR, Friedman DJ, Forszpaniak C, Andersen PL, Wood MJ. Valacyclovir compared with acyclovir for improved therapy for herpes zoster in immunocompetent adults. *Antimicrob Agents Chemother* 1995;39:1546-53.
- Gnann JW, Whitley RJ. Natural history and treatment of varicella-zoster virus in high-risk populations. *J Hosp Infect* 1991;18:Suppl A:317-29.
- Ormerod LD, Larkin JA, Margo CA, et al. Rapidly progressive herpetic retinal necrosis: a blinding disease characteristic of advanced AIDS. *Clin Infect Dis* 1998;26:34-45.
- Huff JC, Bean B, Balfour HH, et al. Therapy of herpes zoster with oral acyclovir. *Am J Med* 1988;85:Suppl 2A:84-8.
- Morton P, Thomson AN. Oral acyclovir in the treatment of herpes zoster in general practice. *N Z Med J* 1989;102:93-5.
- McKendrick MW, McGill JI, White JE, Wood MJ. Oral acyclovir in acute herpes zoster. *Br Med J* 1986;293:1529-32.
- Tyring S, Barbarash RA, Nahlik JE, et al. Famciclovir for the treatment of acute herpes zoster: effects on acute disease and postherpetic neuralgia: a randomized, double-blind, placebo-controlled trial. *Ann Intern Med* 1995;123:89-96.
- Tyring SK, Beutner KR, Tucker BA, Anderson WC, Crooks RJ. Antiviral therapy for herpes zoster: randomized, controlled clinical trial of valacyclovir and famciclovir therapy in immunocompetent patients 50 years and older. *Arch Fam Med* 2000;9:863-9.
- Cobo M, Foulks GN, Liesegang T, et al. Observations on the natural history of herpes zoster ophthalmicus. *Curr Eye Res* 1987;6:195-9.
- Cobo LM, Foulks GN, Liesegang T, et al. Oral acyclovir in the treatment of acute herpes zoster ophthalmicus. *Ophthalmology* 1986;93:763-70.
- Hoang-Xuan T, Buchi ER, Herbot CP, et al. Oral acyclovir for herpes zoster ophthalmicus. *Ophthalmology* 1992;99:1062-71.
- Tyring S, Engst R, Corriveau C, et al. Famciclovir for ophthalmic zoster: a randomized aciclovir controlled study. *Br J Ophthalmol* 2001;85:576-81.
- Colin J, Prisant O, Cochener B, Lescale O, Rolland B, Hoang-Xuan T. Comparison of the efficacy and safety of valacyclovir and acyclovir for the treatment of herpes zoster ophthalmicus. *Ophthalmology* 2000;107:1507-11.
- Liesegang TJ. Varicella zoster viral disease. *Mayo Clinic Proc* 1999;74:983-98.
- Glesby MJ, Moore RD, Chaisson RE. Clinical spectrum of herpes zoster in adults infected with human immunodeficiency virus. *Clin Infect Dis* 1995;21:370-5.
- Gnann JW, Crumpacker CS, Lalezari JP, et al. Sorivudine versus acyclovir for treatment of dermatomal herpes zoster in human immunodeficiency virus-infected patients: results from a randomized, controlled clinical trial. *Antimicrob Agents Chemother* 1998;42:1139-45.
- Safrin S, Berger TG, Gilson I, Wolfe PR, Wofsy CB. Foscarnet therapy in five patients with AIDS and acyclovir-resistant varicella-zoster virus infection. *Ann Intern Med* 1991;115:19-21.
- Harrison RA, Soong S, Weiss HL, Gnann JW, Whitley RJ. A mixed model for factors predictive of pain in AIDS patients with herpes zoster. *J Pain Symptom Manage* 1999;17:410-7.
- Wood MJ, Johnson RW, McKendrick MW, Taylor J, Mandal BK, Crooks J. A randomized trial of acyclovir for 7 days and 21 days with and without prednisolone for treatment of acute herpes zoster. *N Engl J Med* 1994;330:896-900.
- Whitley RJ, Weiss H, Gnann JW, et al. Acyclovir with and without prednisone for the treatment of herpes zoster: a randomized, placebo-controlled trial. *Ann Intern Med* 1996;125:376-83.
- Wu CL, Marsh A, Dworkin RH. The role of sympathetic nerve blocks in herpes zoster and postherpetic neuralgia. *Pain* 2000;87:121-9.
- Dworkin RH, Perkins FM, Nagasako EM. Prospects for the prevention of postherpetic neuralgia in herpes zoster patients. *Clin J Pain* 2000;16:Suppl 2:S90-S100.
- Volmink J, Lancaster T, Gray S, Silagy C. Treatments for postherpetic neuralgia — a systematic review of randomized controlled trials. *Fam Pract* 1996;13:84-91.
- Kanazi GE, Johnson RW, Dworkin RH. Treatment of postherpetic neuralgia: an update. *Drugs* 2000;59:1113-26.
- Max MB, Schafer SC, Culnane M, Smoller B, Dubner R, Gracely RH. Amitriptyline, but not lorazepam, relieves postherpetic neuralgia. *Neurology* 1988;38:1427-32.
- Kishore-Kumar R, Max MB, Schafer SC, et al. Desipramine relieves postherpetic neuralgia. *Clin Pharm Ther* 1990;47:305-12.
- Rowbotham M, Harden N, Stacey B, Bernstein P, Magnus-Miller L. Gabapentin for the treatment of postherpetic neuralgia: a randomized controlled trial. *JAMA* 1998;280:1837-42.
- Watson CP, Babul N. Efficacy of oxycodone in neuropathic pain: a randomized trial in postherpetic neuralgia. *Neurology* 1998;50:1837-41.
- Bernstein JE, Korman NJ, Bickers DR, Dahl MV, Millikan LE. Topical capsaicin treatment of chronic postherpetic neuralgia. *J Am Acad Dermatol* 1989;21:265-70.
- Galer BS, Rowbotham MC, Perander J, Friedman E. Topical lidocaine

patch relieves postherpetic neuralgia more effectively than a vehicle topical patch: results of an enriched enrollment study. *Pain* 1999;80:533-8.

43. Kotani N, Kushikata T, Hashimoto H, et al. Intrathecal methylprednisolone for intractable postherpetic neuralgia. *N Engl J Med* 2000;343:1514-9.
44. Whitley RJ, Weiss HL, Soong SJ, Gnann JW. Herpes zoster: risk categories for persistent pain. *J Infect Dis* 1999;179:9-15.
45. Wood MJ, Shukla S, Fiddian AP, Crooks RJ. Treatment of acute herpes zoster: effect of early (<48 h) versus late (48-72 h) therapy with acyclovir and valaciclovir on prolonged pain. *J Infect Dis* 1998;178:Suppl 1:S81-S84.
46. Decroix J, Partsch H, Gonzalez R, et al. Factors influencing pain outcome in herpes zoster: an observational study with valaciclovir. *J Eur Acad Dermatol Venereol* 2000;14:23-33.
47. McKendrick MW, McGill JI, Wood MJ. Lack of effect of acyclovir on postherpetic neuralgia. *BMJ* 1989;298:431.
48. Jackson JL, Gibbons R, Meyer G, Inouye L. The effect of treating herpes zoster with oral acyclovir in preventing postherpetic neuralgia. *Arch Intern Med* 1997;157:909-12.
49. Alper BS, Lewis PR. Does treatment of acute herpes zoster prevent or shorten postherpetic neuralgia? *J Fam Pract* 2000;49:255-64.
50. Dworkin RH, Portenoy RK. Pain and its persistence in herpes zoster. *Pain* 1996;67:241-51.
51. Bowsher D. The effects of pre-emptive treatment of postherpetic neuralgia with amitriptyline: a randomized, double-blind, placebo-controlled trial. *J Pain Symptom Manage* 1997;13:327-31.
52. Levin MJ, Barber D, Goldblatt E, et al. Use of a live attenuated varicella vaccine to boost varicella-specific immune responses in seropositive people 55 years of age and older: duration of booster effect. *J Infect Dis* 1998;178:Suppl 1:S109-S112.
53. Oxman MN. Immunization to reduce the frequency and severity of herpes zoster and its complications. *Neurology* 1995;45:Suppl 8:S41-S46.

Copyright © 2002 Massachusetts Medical Society.