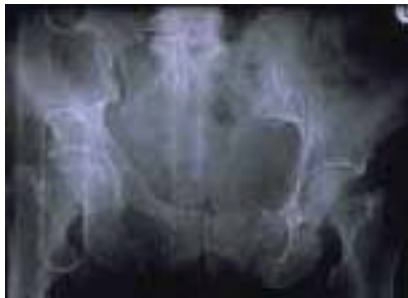

# Initial Management of Pelvic Fractures

by Martin A. Croce, MD, FACS  
Subcommittee on Publications  
Committee on Trauma

## Pelvic Fractures and Associated Injuries

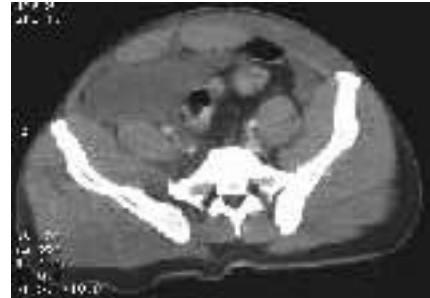- Pelvic ring has no inherent stability and relies on ligamentous support
- Fractures and ligamentous disruptions suggest major forces from trauma
- Injuries typically follow auto/pedestrian, motor vehicle, or motorcycle crashes
- Pelvic fractures are commonly associated with intraperitoneal and retroperitoneal visceral and vascular injuries
- Fractures may lead to rotational instability, vertical instability, or both
- Most hemorrhage results from the low-pressure venous plexus and fractured cancellous bone surfaces
- **Associated hypotension may or may not be related to the pelvic fracture itself, and associated injuries must be actively sought**



A-P view with right sacroiliac disruption and rami fractures from lateral compression



A-P view with both rotational and vertical instability

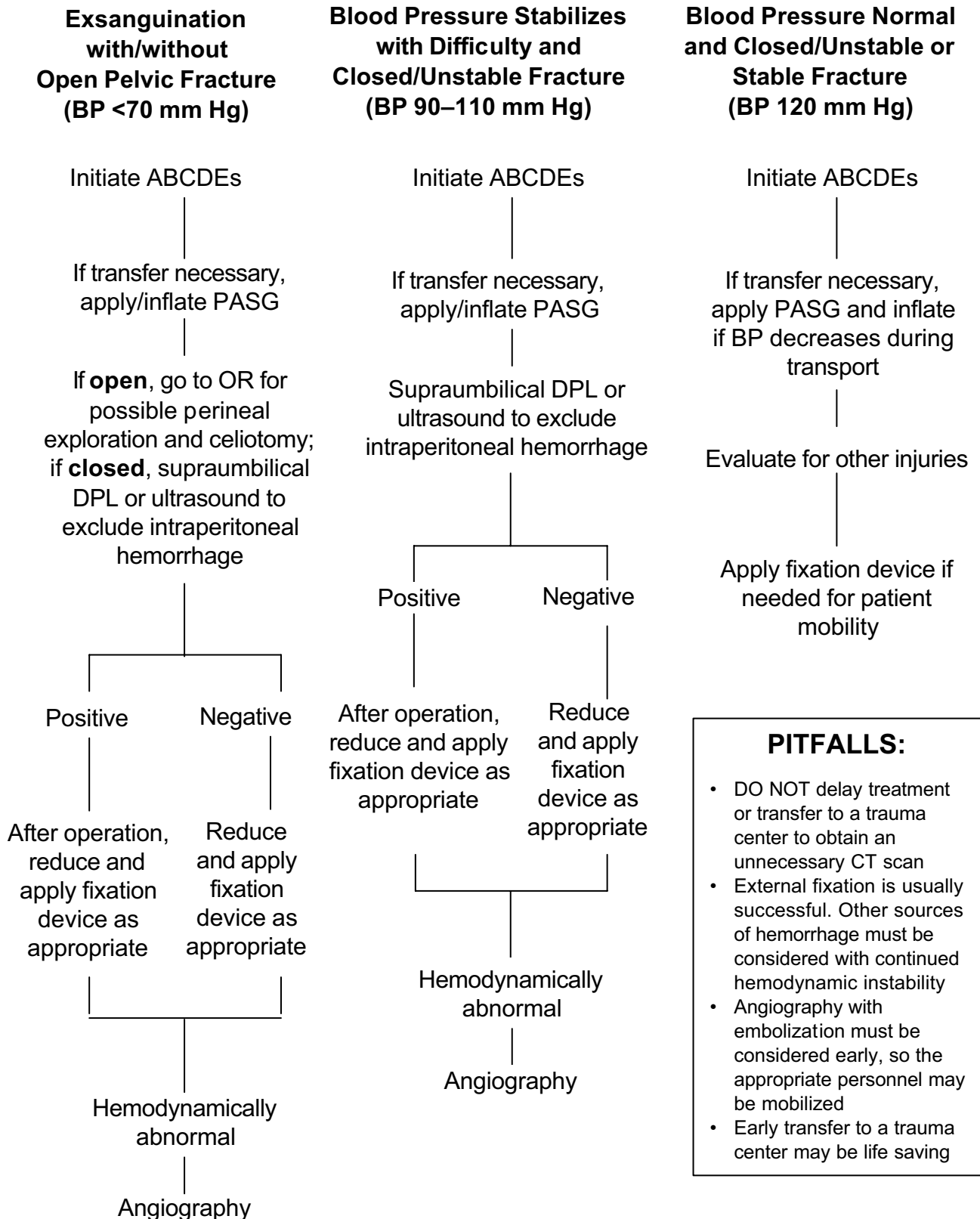


CT demonstrating right sacroiliac fracture and extensive extraperitoneal hematoma

## Initial Assessment

1. ABCDEs—Associated injuries to the head, chest, abdomen, and long bones are common and may be caused by hypotension.
2. Physical Examination—Ecchymosis about the flank and pubis and scrotal hematoma are suggestive of pelvic fracture. Blood at the urethral meatus signifies urethral injury. Presence of blood on vaginal and rectal exam suggests an open pelvic fracture. Stability of the pelvic ring should be tested by **gentle** manual palpation and should be performed **only once** to minimize further hemorrhage from fractures sites.
3. X Rays—Only a single anterior-posterior view is necessary.
4. Pneumatic Antishock Garment (PASG)—May be useful as a temporary stabilizing device for intrahospital transport and prior to trauma center transfer.

# Pelvic Fracture Management Algorithm\*



**PITFALLS:**

- DO NOT delay treatment or transfer to a trauma center to obtain an unnecessary CT scan
- External fixation is usually successful. Other sources of hemorrhage must be considered with continued hemodynamic instability
- Angiography with embolization must be considered early, so the appropriate personnel may be mobilized
- Early transfer to a trauma center may be life saving

\*ATLS, 1997.

This publication is designed to offer information suitable for use by an appropriately trained physician. The information provided is not intended to be comprehensive or to offer a defined standard of care. The user agrees to release and indemnify the American College of Surgeons from claims arising from use of the publication.