


Initial Management of Maxillofacial Injuries

American College of Surgeons
Committee on Trauma
April 1997



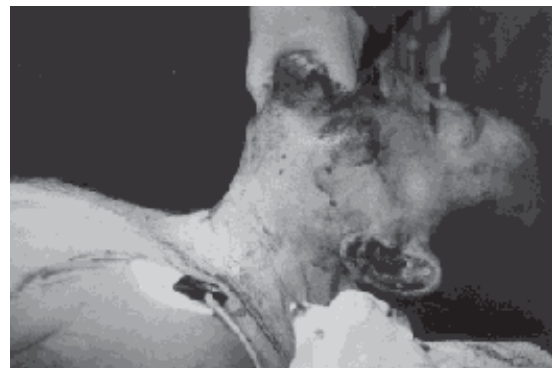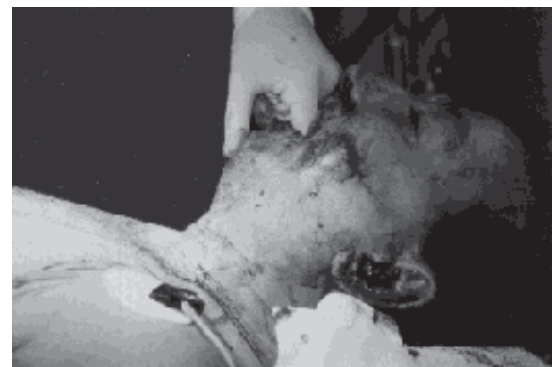Initial Management of Maxillofacial Injuries

by Alan E. Seyfer, MD, FACS
Member, ACS Committee on Trauma

PRIMARY SURVEY

AIRWAY WITH CERVICAL SPINE CONTROL

Look for airway obstruction from foreign bodies (such as broken teeth, dentures).



If the mandible is fractured, the tongue may fall posteriorly (top photo), blocking the airway. The chin lift and/or surgical airway could be lifesaving (bottom photo). (Photos courtesy Richard J. Mullins, MD, FACS. From Feliciano DV, Moore EE, Mattox KL (eds): *Trauma*. 3rd ed. Appleton & Lange, Stamford, CT, 1996, p. 293.)

BREATHING—assess ventilatory function.

BLEEDING—can usually be controlled with direct pressure.

CIRCULATION—once airway is established and local bleeding is controlled, treat hypotension.

DISABILITY—assess for vision/pupillary responses and for nerve injury. (Facial nerve: raise eyebrows; close eyelids tightly; show teeth/purse lips.)

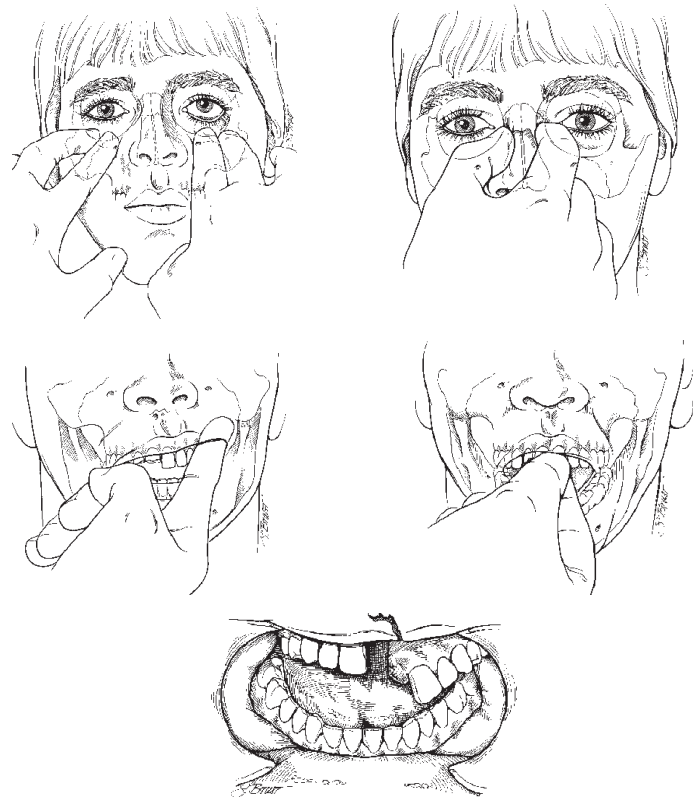
This publication is designed to offer information suitable for use by an appropriately trained physician. The information provided is not intended to be comprehensive or to offer a defined standard of care. The user agrees to release and indemnify the American College of Surgeons from claims arising from use of the publication.

SECONDARY ASSESSMENT

Examine the **skull and spine** for fractures. (With neck immobilized, gently palpate skull and C-spine for tenderness or stepoffs.)

Examine the maxillofacial areas for fractures.

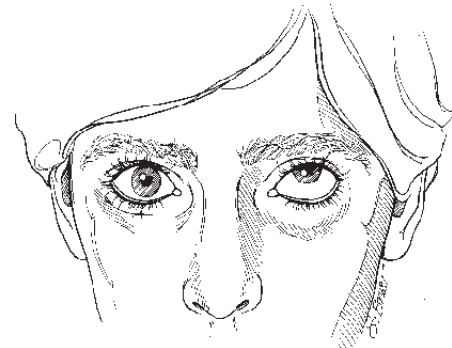Palpate orbital rims, nose, and both jaws for step-off fragments.



Assess stability of upper jaw and examine for abnormal occlusion or gaps between teeth.

Assess for visual disturbances and ocular motility. Check movement of eyes for normal motion, paralysis, or entrapment of extraocular musculature.

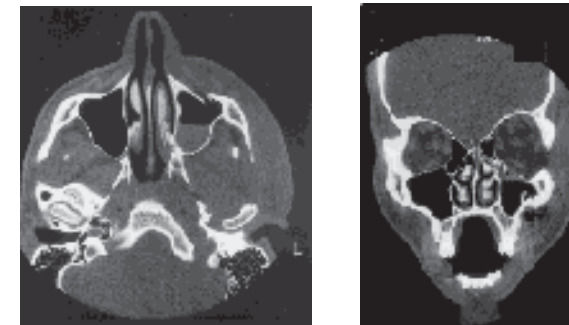
Example: patient tries to look upward



Failure of eye to move may indicate entrapment.

RADIOLOGIC STUDIES

With neck immobilized, obtain lateral cervical spine X-ray to assess for fracture.

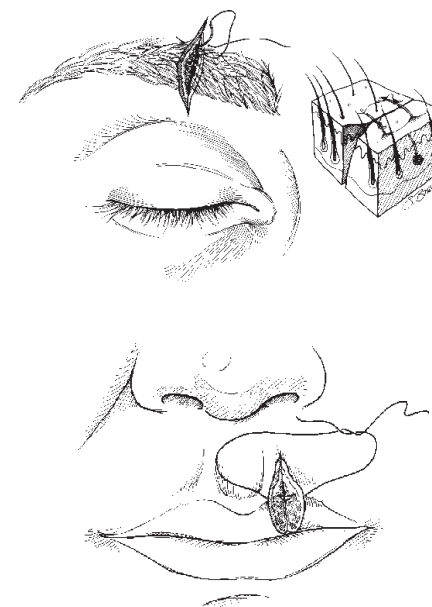


Later, CT scans should be guided by clinical suspicion and are the standard for maxillofacial fracture assessment.

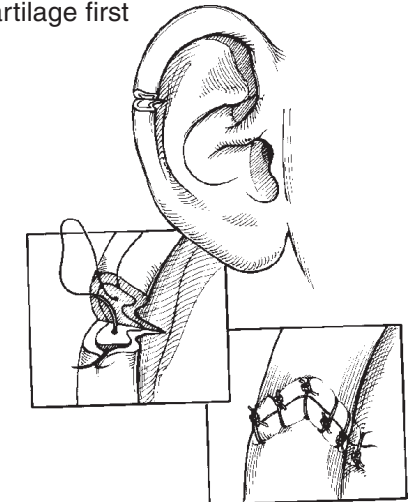
MANAGEMENT OF SOFT TISSUES

In general, the facial soft tissues should be conservatively debrided of irregular tissues, cleansed, and meticulously closed with fine everting sutures. Caution is required at areas where injured underlying structures can be missed.

- **Special caution** is also required in areas that contain visible landmarks, including the borders of the eyelid, eyebrows, lips, nose, columella (skin below nasal septum), and external ear.



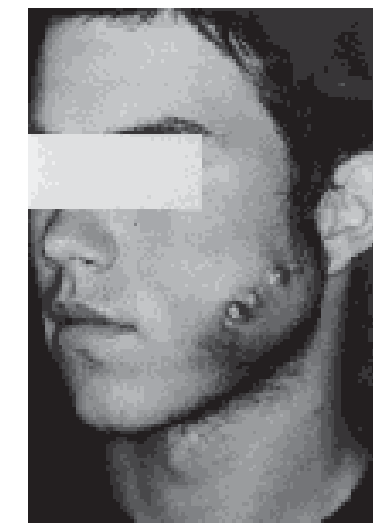Close cartilage first



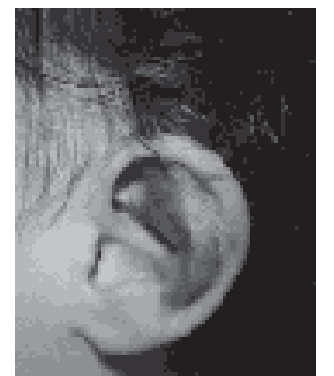
Avoid linear scars (notching)

- **Special caution** is also required with soft tissue injuries overlying important anatomic structures:

- * middle third of cheek (parotid duct) to avoid parotid fistula
- * margin of mandible and zygomatic arch (facial nerve)
- * canthal region (medical corner) of eyelids (lacrimal ducts)



Parotid duct laceration



Ear hematoma*

- * ear hematomas (as shown) must be evacuated to prevent cartilage necrosis (cauliflower ear)



American College of Surgeons
55 East Erie Street
Chicago, IL 60611-2797

This publication is designed to offer information suitable for use by an appropriately trained physician. The information provided is not intended to be comprehensive or to offer a defined standard of care. The user agrees to release and indemnify the American College of Surgeons from claims arising from use of the publication.