

Management of Hand Injuries

by Alan E. Seyfer, MD, FACS
Member, ACS Committee on Trauma

Suspicion of Injury and Testing

Any injury that penetrates the skin of the hand can cause a deep-space infection or may injure an underlying:

- Nerve
- Tendon
- Artery

Lacerations

- Assume that all the important structures are injured until they are specifically **tested**.
- Use direct *pressure* and *elevation* to control bleeding—**do not use blind clamping!**
- Beware of nerve and tendon injuries, especially in children and others who cannot fully cooperate with the examination.
- Leave the wound open.

Precautions

- Test for nerve injury (numbness, paralysis) **before** administering any anesthetic.
- Administer the digital anesthetic block to the dorsum of the hand.
- **Never** inject the digit itself, which may result in *necrosis*. Avoid injecting the web space.

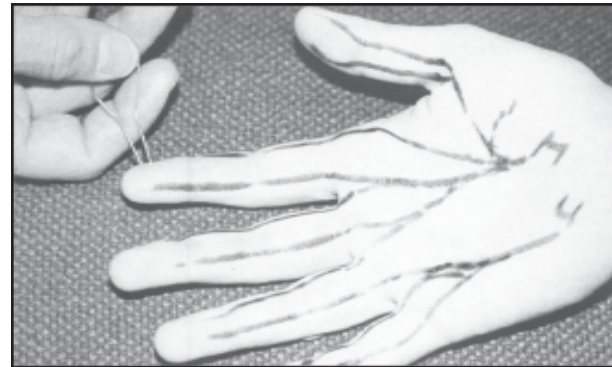This publication is designed to offer information suitable for use by an appropriately trained physician. The information provided is not intended to be comprehensive or to offer a defined standard of care. The user agrees to release and indemnify the American College of Surgeons from claims arising from use of the publication.

©1994 American College of Surgeons

To Determine Nerve Injury

Test for Sensation

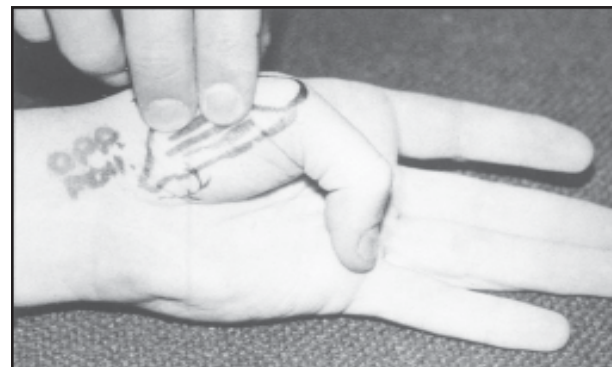Touch the finger lightly on both sides of the pulp to determine two-point discrimination (NL = 4 to 6mm).



Each digital nerve is tested for sensation.

Test for Motor Skills

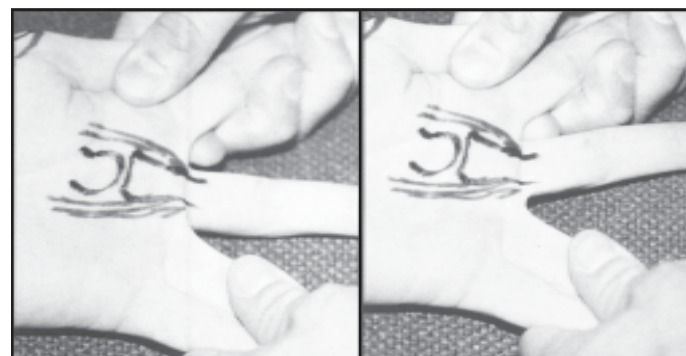
Palpate the opponens muscle (motor branch of median nerve) as thumb touches small finger.



Opponens muscle is palpated to test motor nerve integrity.

Test Interosseus Muscles (motor branch of ulnar nerve)

While grasping the outer fingers, have the patient move the middle finger as a "windshield wiper."

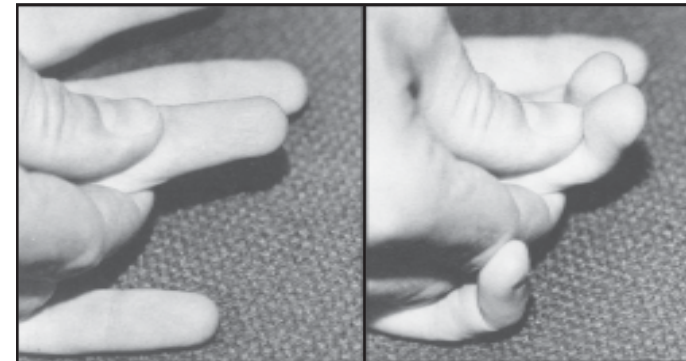


Patient moves middle finger to test interosseus muscles (ulnar nerve).

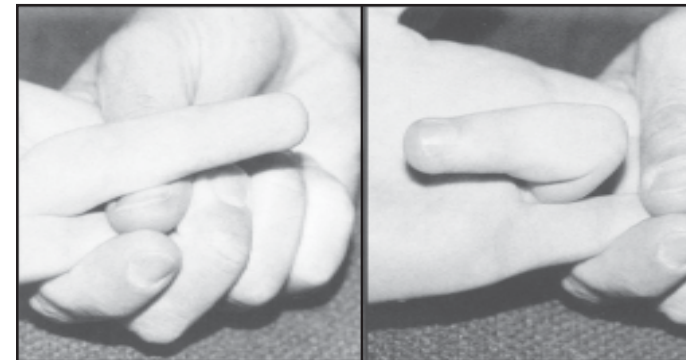
To Determine Tendon Injury

Test for Flexor Tendons

Palpate deep (profundus) and superficial flexor tendons of each finger.



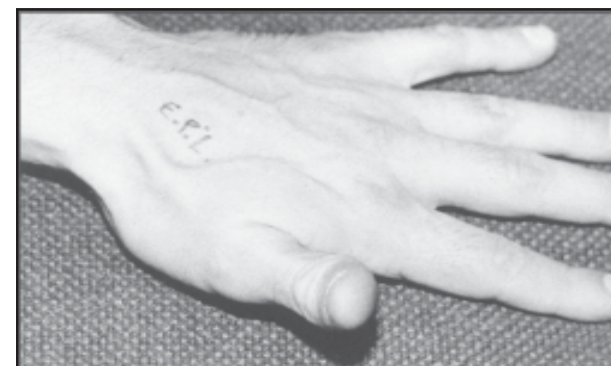Deep (profundus) flexor tendon of each finger is tested.



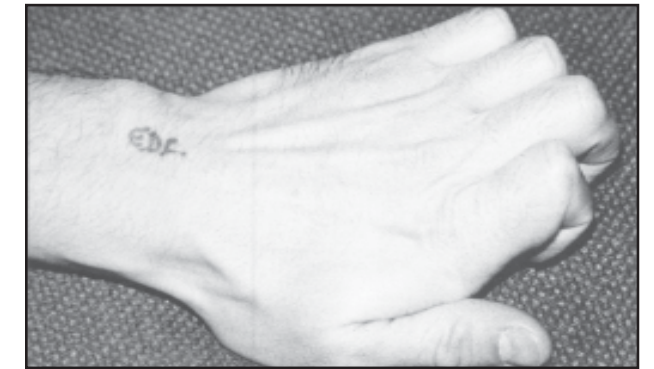Superficial flexor tendon of each finger is tested.

Test for Long Extensor Tendons

Have the patient hold fingers straight and lift thumb, then curl fingers and lift knuckles.



Long extensor tendon of thumb is tested.

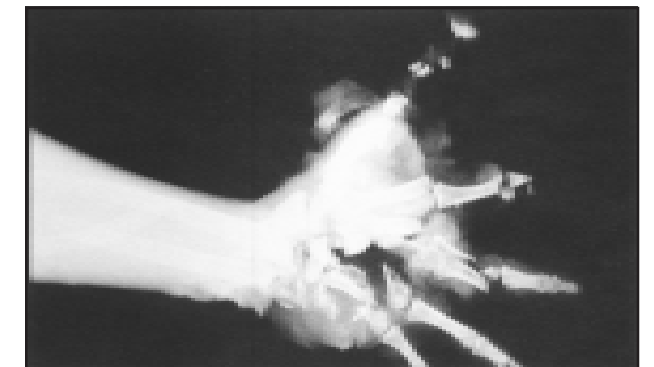

Long extensor tendons of fingers are tested.

To Determine Fractures

Fractures are usually obvious and can be confirmed by posterior-anterior and lateral roentgenograms.

To treat most fractures, consult with a hand surgeon.



Infection

Prevention

Most wounds of the hand can be safely left *open* to heal by secondary intention. This procedure usually avoids serious infection.

Puncture wounds require close follow up, because they can lead to severe infections.

Give tetanus immunization when appropriate.

Surgical Emergencies Resulting from Infection

Signs of tenosynovitis are:

- diffuse swelling and tenderness
- pain on passive stretch of the digit

Signs of purulent arthritis are:

- joint tenderness
- exquisite sensitivity (pain) on any motion of the joint